

Topical administration of *Averrhoa bilimbi* Linn. Leaves crude extract prevents UVB-induced oxidative damage in albino mice

Student Researchers: Precious Love A. Agena, Coren Jane P. Albay, Celestine L. Apusen, Mary Rose M. Arago, Janina Camille E. Catapang & Rheinmark Lloyd S. Siapco

Faculty Researchers: Adelina P. Abarintos, MD& Citadel A. Panganiban, RMT

Abstract - Exposure to sunlight triggers stimulation of hormone production, promotes skin cell regeneration and synthesizes Vitamin D activation. Excessive unprotected contact to sunrays, however, leads to acquisition of skin-related complications and to a higher risk of gaining diseases. This study assessed photoprotective properties of crude extracts of *Averrhoa bilimbi* Linn. leaves in the ultraviolet region (UV) (200-400nm). The crude extract of the plant was tested against UVB-induced oxidative damage in Albino mice. Biochemical assays such as lipid peroxidation together with histopathological examination were performed. The study revealed that the 4% topical extract treatment reduced the effect of UV light-induced photo-aging in mice skin by decreasing Malondialdehyde (MDA) level by up to 50% compared to an irradiated control group. Histopathological evaluation also indicated a photo-protective activity on the extract treated mice skin with minimal signs of histological change and mild dermatitis after UV exposure. Subacute moderated dermatitis is diagnosed in 3% of the treated group whereas 2% of the treated group showed chronic moderated dermatitis. Decreasing inflammatory condition was examined in increasing concentration of extract which showed strong-to-moderate absorption of UV radiation.

Keywords - *Averrhoa bilimbi* Linn, lipid peroxidation, phenolics, photoprotective, UV light

INTRODUCTION

Minimal ultraviolet radiation (UV) is considered beneficial to human health. Recently, however, prevalence of various diseases is associated with solar UV radiation and has been alarmingly increasing (Parkin et. al., 2011). Such damages include skin cancers, sunburns, cataracts and accelerated skin aging (World Health Organization (WHO), 2009).

Skin cancer is the leading disease caused by UV light (Tran et. al., 2012). In relation to this, ozone layer contributes to acquisition of skin cancer. Lesser ozone in the atmosphere means more ultraviolet radiation strikes Earth (WHO, 2009) causing more skin cancers, retinal damage, and other potential harms (Bambal et. al, 2011, Environmental Working Group (EWG), 2011; National Geographic News (NGN) 2010). Meanwhile, UV range is the most

significant spectrum of sunlight that causes photo aging and skin cancer (Gilchrest et al., 1999).

UV rays (UVR) is subdivided into UVA (300-400nm), UVB (280-315 nm) and UVC (100-280nm) (Kaur and Saraf, 2010; WHO, 2009). UVR – UVB is the most cancerous range of terrestrial radiation. More than 90 % of solar radiation that reaches the human is UVA which is considered as the aging ray that penetrates deep into the epidermis and dermis of the skin. It is about 1000 times more effective in the production of an immediate tanning effect which is caused by darkening of the melanin in the epidermis. Also, it causes premature photo-aging of the skin, skin sagging rather than wrinkling and suppression of immunological functions. After exposure to UVA, generation of singlet oxygen, H₂O₂ and free radicals occurred. These can cause damage to cellular proteins, lipids, and saccharides. It can produce structural damage to the DNA, impair the immune system, and lead to cancer. (Narayanan, 2010)

On the other hand, UVB radiation is regarded as the burning ray and it makes up 4 to 5 % of UV light. UVB is a minor but the most active constituent of solar light which is 1000 times more capable of causing sunburn than UVA. In addition, this ultraviolet is also more genotoxic than UVA and acts mainly in the epidermal basal cell layer of the skin. It causes stimulation of DNA synthesis, free radical production in the skin, cell cycle growth arrest, photo-aging and photo-carcinogenesis. It induces skin cancer such as squamous and basal cell carcinoma due to DNA damage. Along with, it lowers the skin's immune defense system (Svobodova et al., 2003).

Moreover, UVC radiation is very dangerous to all forms of life, even with only very short exposures. It is extremely damaging to the skin. Auspiciously, it is completely absorbed by molecular oxygen and ozone in the earth's atmosphere and no solar radiation of wavelengths below 280 nm reaches the surface of the earth (Narayanan, 2010; WHO 2010).

Interest about herbal medicines is increasing due to their efficacy, lesser side effects and relatively economical cost (Mosihuzzaman and Choudhary, 2008). *Averrhoa bilimbi*, under Oxalidaceae family known as bilimbi, cucumber tree, tree sorrel (English), Kamias (Tagalog), belimbing asam (Indonesian) tiriguro (Spanish), is a fruit cultivated in the Philippines (Orwa et al., 2009) with varied medicinal properties (Anitha et al., 2010). It is an attractive, long-standing tree, reaching 5-10m in height. *A. bilimbi* is a tropical tree with slow growth in shady or semi-shady situations and prefers complete exposure to sunlight (Orwa et al., 2009).

The phytochemical constituents of *Averrhoa bilimbi* are as follows: plant extract has phenolics, amino acids, citric acids, cyanidin-3-O-h-D-glucoside, potassium ion, sugars and vitamin A (Nagmoti et al., 2010). Also, it has flavonoids, saponins and triterpenoids (Anitha et al., 2010) with flavones such as luteolin and apigenin (Zakaria et al., 2007). In addition, physicochemical

characteristics such as total soluble solids, oxalic acids and vitamin C are also present in the plant (De Lima et al., 2001).

Previous researches provide evidences that *A. bilimbi* has significance in medicine. Anitha et al. (2010) revealed the pharmacognosy of *Averrhoa bilimbi* Linn. Medicinally, it is used as antibacterial (Das et al., 2011; Karon et al., 2011; Zakaria et al., 2007) and antifungal effect (Nazmul et al., 2010). Nagmoti (2010) conducted a study about its hepatoprotective activity. Hypoglycemic and hypolipidemic activity of the semi-purified fractions of its leaf extract was also reported (Ambili et al., 2009). Moreover, the fruit is folklorically used as a treatment for cough, beri-beri and biliousness. In addition, it is used as a cure for fever, inflammation, rectal bleeding and internal hemorrhoids. On the other hand, leaves are utilized to treat venereal disease while its decoction is taken to relieve rectal inflammation. The plants' flower infusion is effective against cough and thrush. Additionally, prickled bilimbi paste is coated over the body to accelerate recovery right after a fever (Anitha et al., 2011; Orwa et al., 2009).

Plants with high levels of bioflavonoids were utilized in anti-solar studies for it has UV light filtration activity. These said studies include *Spathodea campanulata* L., *Pongamia pinnata*, (L) pierre, fabaceae (Patil et al., 2009; Shenoy et al., 2010; Solovchenko and Schmitz-Eiberger, 2003). Flavonoids are found ubiquitously in plants (Spencer, 2008). *A. bilimbi* has been regarded as rich with the said chemical, specifically luteolin and apigenin (Zakaria et al., 2007). In the past decade, antioxidant activity of phenolics has been given much attention. Flavonoids such as quercetin, luteolin and catechins surpass the effectivity of Vitamin C, Vitamin E and β -carotene. Therefore, prevention of UV- induced damage and lipid peroxidation will be achieved with these phenolics (Svobodová et al., 2003). Apigenin, a normally occurring flavone in the plant (Zakaria et al., 2007) was investigated and found to be efficient in the prevention of UVA/B-induced skin carcinogenesis in SKH-1 mice (Shukla, 2010). Mc Vean (2001) concluded that this phenolic compound may prevent UV-induced skin tumorigenesis with the inhibition of cell cycle and cyclin-dependent kinases.

Photoabsorbance and protective effect of *Averrhoa bilimbi* against UVB-induced skin damage has not been studied yet. In this study, the researchers determined the absorbance level of the ethanolic extract of *Averrhoa bilimbi* leaves with UV-visible spectrophotometer and evaluated the response of hairless Albino mice exposed to UV light. Biochemical assays including lipid peroxidation together with histopathological examination were the parameters of the photo-protective effect based on the study of Sachdeva (2011).

MATERIALS AND METHODS

Collection and Identification (Sachdeva et al., 2011)

Leaves of *Averrhoa bilimbi* were collected from a local tree in San Pedro, Bauan, Batangas between the months of May to June. These were identified by a botanist from the University of the Philippines-Los Baños Herbarium.

Preparation of Extract (Ojei, et.al., 2010, Tiwari et al., 2011)

The ethanolic extracts of the leaves of the plants were prepared. Leaves samples were thoroughly cleaned with sterile distilled water. 300g of ground leaves were soaked in ethanol (95%) for 72 hours. The extracts were filtered and evaporated under vacuum using laminar flow. The residues of the extracts were stored in clean bottles.

Phytochemical Screening (Tiwari et al., 2011)

Alkaline Reagent Test: Extracts were treated with few drops of sodium hydroxide solution. Formation of intense yellow colour, which became colourless on addition of dilute acid, indicated the presence of flavonoids.

Ferric Chloride Test: Extracts were treated with 3-4 drops of ferric chloride solution. Formation of bluish black colour indicated the presence of phenols.

Preparation of Laboratory Animals (Sachdeva et al., 2011)

Male Albino mice weighing 15–25 g were purchased from Arranque Market-C.M Animal House in Recto Avenue, Manila. The Animal Ethical Committee of the Bureau of Animal Industry under the Department of Agriculture approved the experimental protocols based on the guidelines on the control and supervision of experimental animals. The mice were put in plastic bottom cages, properly fed and given sufficient water. To minimize free radical production due to trauma from the shaving blade, hair removing cream was used. Using Veet cream (Kosmetik E. Ritter, Switzerland), the hair on demarcated areas of approximately 4 cm² on the dorsal surface of each mouse were removed.

UV light Exposure Conditions and Development of UVB-Induced Oxidative Damage in Mice (Sachdeva et al., 2011)

The mice were divided into five groups with 10 animals each. Group I served as control. Group II animals received five-minute UV exposure twice a day and served as irradiated control. The test groups III, IV and V received UV radiations and two, three and four percent leaf extract treatment, respectively. The treatment was given four hours prior to UV exposure as per the protocol. All the animals were kept inside a solar simulator (designed in the laboratory and

fitted with UV lamp) at a distance of 40 cm from the UV light source. The bulb gave the full spectrum of UV radiation, i.e., 280 - 315 nm, simulating the full solar spectrum. UV exposure was controlled by time of exposure. Exposures were given twice daily for five minutes. For the mice receiving topical extract treatment, the dorsal skin was treated with extract four hours prior to each UV radiation exposure. The extract was delivered at a dose of 10 $\mu\text{l}/\text{cm}^2$ area of the skin with micropipette. The animals were treated for three, seven, 11 and 15 days following which the skin were excised and preserved in a chilled sachet.

Biochemical Determinations

Lipid Peroxidation Assay (Sachdeva et al., 2011)

Lipid peroxidation was assessed in all groups by estimating 2-thiobarbituric acid reacting substance, i.e., malondialdehyde (MDA). To 0.2 ml homogenized sample, 0.2 ml of 8.1% sodium lauryl sulphate and 1.5 ml of 20% acetic acid solution (pH adjusted to 3.5 with sodium hydroxide) were added. Then 1.5 ml of 0.8% aqueous solution of thiobarbituric acid (TBA) was added. The mixture was made up to 40 ml with distilled water and heated in a water bath at 95°C for 60 min. In cooling water one ml of distilled water and 5.0 ml mixture of butanol and pyridine (15:1 v/v) were added. After centrifugation at 4000 rpm for 10 minutes, absorbance of the organic layer was read at 532 nm.

Histopathological Studies (Sachdeva et al., 2011)

For histopathological investigation, the animals were treated for 15 days following which the skin were excised and used for histopathological studies. Skin biopsies from dorsal portions of unirradiated control group, irradiated control group/UV-irradiated and treated groups were stored in 10% formalin, embedded in paraffin, and sectioned. The sections were stained with aqueous haematoxylin and alcoholic eosin stain for routine examination of the tissues. These sections were also analyzed for changes in integrity of vessels, inflammatory infiltrates, fibrosis and appearance of edema.

Statistical Analysis

The experimental results obtained were expressed as mean \pm standard error of mean (SEM). All measurements were carried out in triplicate. Means were compared for statistically significant differences by one-way analysis of variance (ANOVA) using SPSS (version 17) for Windows with a 95% confidence interval.

RESULTS

Skin cancer is the leading disease caused by UV light (Cancer Facts & Figures (CFF), 2010; World Health Organization (WHO), 2009) by producing free radicals. Excessive unprotected contact to sunrays, however, leads to acquisition

of skin-related complications and to a higher risk of gaining diseases. In this study, the researchers determined the photoabsorptive effect of *Averrhoa bilimbi* leaves in addition to its hepatoprotective activity, antibacterial and antifungal effect, hypoglycemic and hypolipidemic property. Also, evaluation of the response of hairless Albino mice as exposed to UV light was studied. Biochemical assays including lipid peroxidation together with histopathological examination were the parameters of the photo-protective effect based on the study by Sachdeva (2011). Flavonoids and phenolics have been the focus of this study due to their photoabsorptive property

Results of Phytochemical Screening

Figure 1 presents the screening test of biochemical compounds present in the extract subjected for photoabsorptive property. For the detection of flavonoids, extract treated with few drops of sodium hydroxide formed intense yellow color, which became colorless after adding diluted acid. This result indicated the presence of flavonoids. On the other hand, screening for phenolics using ferric chloride test showed positive result upon adding 3-4 drops of ferric chloride. Bluish black color indicated the presence of phenolic.

Figure 1
Phytochemical Screening Result

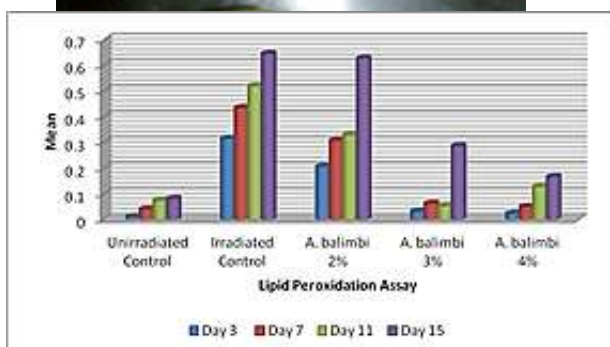


Figure 2
Levels of Skin Malondialdehyde (Lipid Peroxidation Assay) in unirradiated and irradiated groups

Figure 2 presents the lipid peroxidation assay (absorbance) in unirradiated and irradiated groups with 2%, 3% and 4% Averrhoa bilimbi linn. extract. There was a significant increase of lipid peroxides in the form of Malondialdehyde in the irradiated group receiving five-minute exposure to ultraviolet light and decreasing amount of the treated groups with Averrhoa extract. It was observed that there is a minimum absorbance of lipid peroxides in unirradiated control showing least concentration level.

However, among the Averrhoa bilimbi extract, a small percentage of concentration (2%) has the highest amount of malondialdehyde that was conducted on specified days. The days of exposure implies a direct relationship between the length of time and amount of lipid peroxides (MDA) present in the skin of Albino mice.

Table 1
Mean comparison of the Groups Exposed to UV light

	Mean Square	Sig.	Decision
Between Groups	6.817	*0.000	Highly Significant
Within Groups	1.001		
Total	7.818		

*The mean difference is significant at the .05 level.

A significant difference in oxidative damage was noted between unirradiated, irradiated groups with treatment (2%,3%,4%) ($p > 0.05$) is observed in Table 1. Between Groups has sig. 0.000 which is highly significant.

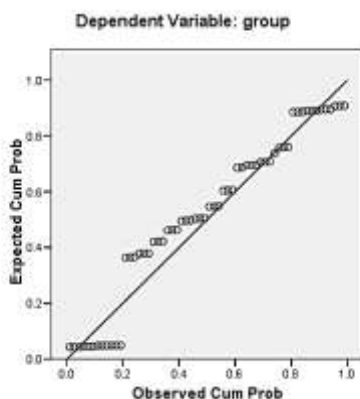


Figure 3
Normal P-Plot of Regression Standardized Residual

Figure 3 shows normal P-Plot of regression standardized residual indicating precision of results among five groups (irradiated control, un-irradiated control, treated groups). There was a strong relationship between the dependent variable y_i and the p-vector of regressors.

Histopathological Results

Figure 4 presents histopathological results for the irradiated control group which showed a progressive damage to both epidermis and dermis at the end of 15 days. The epidermis presented a focal epithelial necrosis with neutrophil infiltration. There is congestion and infiltration with neutrophils and mononuclear cells; many inflammatory cells such as neutrophils, macrophages, lymphocytes. Moreover, fibroblastic cell proliferation and increased collagen matrix formation, proliferation of epithelial cells into dermis around hair follicles and sebaceous glands were observed. Furthermore, focal epithelial necrosis and hyperplasia with focal necrotizing dermatitis were clearly indicated in UV-treated skin sample. In the extract-treated group (2%), epithelia keratinization has become prominent. There is increased fibroblastic proliferation and increased interstitial collagen matrix formation, congestion with many minute hemorrhagic foci just below the epidermis, many neutrophils and macrophages and some lymphocytes are present in the dermis.

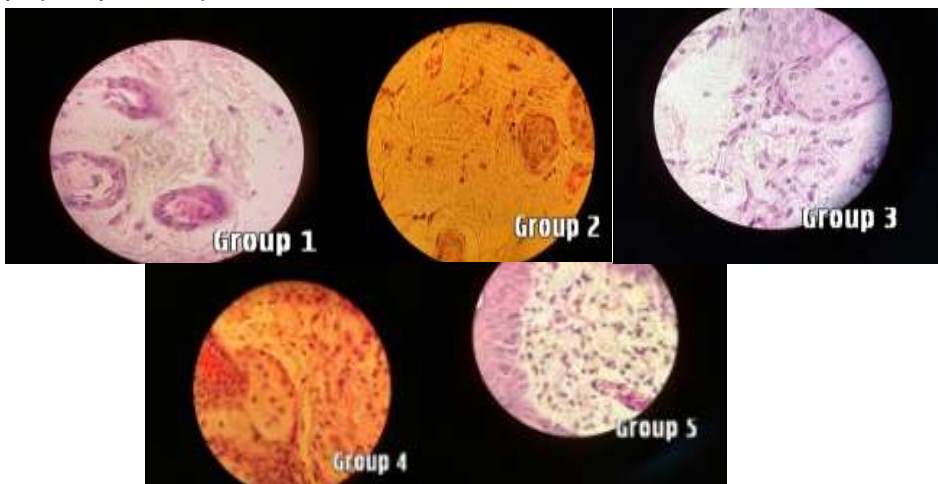


Figure 4
Histopathological Evaluation of Unirradiated, Irradiated and Treated Skin of Albino Mice

However, the 3%-treated group, there was reduction of UV-light effect. Layer appear to decrease in some areas and some epithelial cells show clear spaces around nuclei which are pushed to one side were observed in the epidermis. On the other hand, there was increased proliferation of fibroblasts with increased interstitial collagen matrix formation, macrophages and lymphocytic

infiltration with many neutrophils in the dermis. Group 2 with 4% Averrhoa treatment, there is reduced proliferation of fibroblast with infiltration of some lymphocytes. In comparison with the unirradiated control, epithelial cells in the epidermis, hair follicles, and sebaceous glands that have extended into the dermis appear normal. In UV-irradiated mice skin morphological changes specifically neutrophil infiltration along with epithelial necrosis were observed. However, the treated mice indicated reducing effect of UV-exposure to skin.

DISCUSSION

Lipid peroxidation assay refers to the oxidative degradation of lipids. It is the process in which free radicals steal electrons from the lipids in cell membranes, resulting in cell damage. On the other hand, malondialdehyde which was measured in this assay is the product of polyunsaturated lipids degraded by reactive oxygen species (Simsek et. al., 2011). In this study, it was observed that there's a minimal amount of malondialdehyde in the unirradiated control and maximal level in an irradiated control due to the production of reactive aldehyde causing toxic stress in cells. Basically, the production of aldehyde is a biomarker in the measurement of the level of oxidative stress in an organism (Simsek et. al., 2011).

In Figure 1, the highest amount of malondialdehyde was formed in irradiated group due to the oxidative stress in Albino mice. Comparing the result of unirradiated to irradiated group, malondialdehyde in the latter group was minimal due to the absence of exposure to the ultraviolet light causing overproduction of free radicals in the skin. Along with, decreasing concentration of treatment was parallel with the increasing absorbance of lipid peroxides showing the ability of the extract to absorb the ultraviolet light. In relation with this, sunscreen property is attributed to the presence of some naturally occurring photoabsorptive compounds like flavonoids which are produced by the plants that are subjected to extraordinary amounts of solar radiation in order to protect sensitive parts from the damage (Shenoy et. al., 2010; Svobodova et.al., 2003) In relation to this, *Nyctanthes arbortristis* L. and *tagetes erecta* L. have been proven of sunscreen activity which contain phenolics and flavonoids. (Bambal et. al, 2011) In the present study, biochemical present in the extract, flavonoids, specifically, apigenin and luteolin together with phenolic serve as the active photo-absorptive component that traps the ultraviolet light in damaging the cells. This is consistent with the study of Solovchenko and Schmitz-Eiberger that also confirmed the significance of skin flavonoids for UVB-protection present in apple fruits (2003). Moreover, other properties noted are the antioxidant and anticancer effect of the extract brought by apigenin compound present in common fruits extract fighting against the free radicals formed in the dorsal skin of Albino mice (Shukla and Gupta, 2010).

Histopathological results presented the condition of the skin after exposure to UV light. Increasing severity of skin inflammation is parallel to the decreasing concentration of treatment. Unirradiated control possess normal

epidermal and dermal part which has contrasting effect to the irradiated control with necrotic skin. Mild dermatitis is the characteristic of treated group with 4% extract. Comparing the result to the irradiated group, significant difference was observed. On the other hand, subacute moderated dermatitis is diagnosed to 3% treated group whereas 2% treated group showed chronic moderated dermatitis.

Thus, decreasing amount of MDA in increased concentration of *Averrhoa bilimbi* L. leaf extract was observed in the lipid peroxidation assay. Meanwhile, decreasing inflammatory condition was examined in increasing concentration of extract. The result showed strong-to-moderate absorption of UV radiation along the whole range and this ability may be due to the presence of flavonoids and phenolics.

CONCLUSION

Human skin is constantly exposed to the UV irradiation present in sunlight. This may induce a number of pathobiological cellular changes. Preventive and therapeutic strategies are extended depending on the knowledge of the molecular mechanism of the UV damages.

Biochemical compounds present in *Averrhoa bilimbi* linn. leaves such as flavonoids, e.g. apigenin and luteolin and phenolics were candidates for the prevention of adverse effect of UV radiation on the skin due to their photoabsorptive property.

REFERENCES

- Ambili, S., Subramoniam A., & Nagarajan, N.S. (2009). Studies on the antihyperlipidemic properties of *Averrhoa bilimbi* fruit in rats. *Planta Medicine*, 75, 11-14.
- Anitha, R., Geetha, R.V., & Lakshmi T. (2010). *Averrhoa bilimbi* Linn – nature's drug store – a pharmacological review. *International Journal of Drug, Development & Research*, 3 (3).
- Bambal, V., Wyawahare, N., Turaskar A., & Mishra, M. (2011). Study of sunscreen activity of herbal cream containing flower extract of *Nyctanthes arbortristis* L. and *Tagetes erecta* L. *International Journal of Pharmaceutical Sciences Review and Research*, 11 (1) 142-146.
- Bhadoriya, U., Suthar, A., Dubey, S., & Aggarwal, N. (2010). Diuretic activity of methanolic extract of leaves of *Salvadora persica* L. *Plant Biology*, 55 (1), 3-7.
- Das, S.C., Sultana, S., Roy, S., & Hasan, S.S. (2011). Antibacterial and cytotoxic activities of methanolic extracts of leaf and fruit parts of the plant

Averrhoa bilimbi. *American Journal Scientific and Industrial Research*, 2 (4), 531-536.

De Lima V.L.A.G., Melo, E.D.A., & Lima, L.D.S. (2001). Physicochemical characteristics of Bilimbi (*Averrhoa Bilimbi* L.). *Revista Brasileira de Fruticultura, Jaboticabal - SP*, 23 (2), 421-423.

Environmental Working Group. (June 23,2011). Retrieved from EWG website, <http://breakingnews.ewg.org/2011sunscreens/sunscreens-exposed/does-sunscreens-damage-skin/>

Gilchrist, B.A., Eller, M.S., Geller, A.C., & Yaar, M. (2012).The pathogenesis of melanoma induced by ultraviolet radiation. *The New England Journal of Medicine*, 340 (17),1341-1348.

Handwerk, B. (2010). Retrieved from NGN website, <http://news.nationalgeographic.com/news/2010/05/100505-science-environment-ozone-hole-25-years/>

Karon, B., Ibrahim, M., Mahmood, A., Huq, A.K.M.M., Chowdhury, M.M.U., Hossain, A., & Rashid, M.A. (2011). Preliminary antimicrobial, cytotoxic and chemical investigations of *Averrhoa bilimbi* Linn.and *Zizyphus mauritiana* Lam. *Bangladesh Pharmaceutical Journal*, 14 (2),127-131.

Kaur C. D.,& Saraf S. (2010). In vitro sun protection factor determination of herbal oils used in cosmetics. *Pharmacologyonline*, 2, 22-25.

Mcvean, M., Xiao, H., Isobe, K., & Pelling, J.C. (2000). Increase in wild-type p53 stability and transcriptional activity by the chemopreventive agent apigenin in keratinocytes. *Carcinogenesis*, 21 (4), 633-639.

Mosihuzzaman, M., & Choudhary, M.I (2008).Protocols on safety, efficacy, standardization and documentation of herbal medicine. *International Union of Pure and Applied Chemistry*, 80 (10), 2195-2230.

Nagmoti, D.M., Yeshwante, S.B., Wankhede, S.S., & Juvekar A.R. (2010).Hepatoprotective effect of *Averrhoa bilimbi* Linn.against carbon tetrachloride induced hepatic damage in rats. *Pharmacologyonline*, 3, 1-67.

Naranayan, D. L., Saladi, R. N., & Fox J. L. (2010). Ultraviolet radiation and skin cancer. *International Journal of Dermatology*, 49, 978-986.

Nazmul, M.H.M., Salmah, I., Syahid, A., & Mahmood, A.A. (2011).In-vitro screening of antifungal activity of plants in Malaysia. *Biomedical Research*, 22 (1), 28-30.

- Ojei, J., Ibrahim, T.A., & Iyabo, O. (2010) Comparing The Antibacteria Activity Of Ethanolic Extract Of Vernonia amygdalina and Occimum gratissimum with some Antibiotics of choice. *The Internet Journal of Tropical Medicine*.6 (2). DOI: 10.5580/241f
- Orwa et al., (2009). Agroforestry Database 4-5. Retrieved from http://www.worldagroforestry.org/treedb2/AFTPDFS/Averrhoa_bilimbi.a
- Parkin DM., Mesher D., & Sasieni P. (2011). Cancers attributable to solar (ultraviolet) radiation exposure in the UK in 2010. *British Journal of Cancer*, 105, 566-569. doi:10.1038/bjc.2011.486
- Patil, V.V., Patil, S.B., Kondawar, M.S., sNaikwade, N.S., & Magdum, C.S. (2009). Study of methanolic extract of flower of *Spathodea campanulata* L. as an anti-solar. *International Journal Green of Pharmacy*, 3, 248-9.
- Sachdeva, M., Khary, M.D., Aljarbou, A., & Katyal, T. (2011). Photoprotective effects of hydroalcohol *Tagetes erectus* extract against UV-induced oxidative damage in mice. *Tropical Journal of Pharmaceutical Research*, 10 (6), 747-753.
- Shenoy, P.A., Khot, S.S., Chavan, M.C., Takawale, J.V., & Singh, S. (2010). Study of sunscreen activity of aqueous, methanol and acetone extracts of leaves of *Pongamia pinnata* (L.) pierre, fabaceae. *International Journal Green of Pharmacy*, 4 (4), 270-274.
- Shukla, S., & Gupta, S. (2010). Apigenin: a promising molecule for cancer prevention. *NIH-PA Author Manuscript*, 27 (6), 962-978. doi:10.1007/s11095-010-0089-7
- Skin Cancers. (2009). Retrieved from World Health Organization. <http://www.who.int/uv/faq/skincancer/en/index1.html>
- Solovchenko, A., & Eiberger, M.S. (2003). Significance of skin flavonoids for UVB-protection in apple fruits. *Journal of Experimental Botany*, 54 (389), 1977-1984. doi: 10.1093/jxb/erg199
- Spencer, J.P.E. (2010). The impact of fruit flavonoids on memory and cognition. *British Journal of Nutrition*, 104, 40-47. doi:10.1017/S0007114510003934.
- Sunbeds, tanning and UV exposure. (2010). Retrieved from WHO website, <http://www.who.int/mediacentre/factsheets/fs287/en/>
-

- Svobodova, A., Psotova, J., & Walterova, D. (2003). Natural phenolics in the prevention of UV-induced skin damage. a review. *Biomedical Papers*, 147 (2), 137–145.
- Tran et al., (2012). Parents' perceptions of skin cancer threat and children's physical activity. *Preventing Chronic Disease*, 11, 1-10. doi: 10.5888/pcd9.110345
- Tiwari, P., Kumar, B., Kaur, G., Kaur, H., & Kaur M. (2011). Phytochemical screening and extraction: a review. *Internationale Pharmaceutica Scientia*, 1 (1), 98-106.
- Ultraviolet radiation and human health. (2009). Retrieved from WHO website, <http://www.who.int/mediacentre/factsheets/fs305/en/index.html>
- Zakaria, Z.A., Zaiton, H., Henie, E.F.P., Mat Jais, A.M., & Zainuddin, E. (2007). In vitro antibacterial activity of *Averrhoa bilimbi* L. leaves and fruits extracts. *International Journal of Tropical Medicine*, 2 (3), 96-100.